Available online at www.sciencedirect.com

SciVerse ScienceDirect

British Journal of Oral and Maxillofacial Surgery 52 (2014) 392–395

BRITISH Journal of Oral and Maxillofacial Surgery

www.bjoms.com

Review

Osteoradionecrosis—A review of current concepts in defining the extent of the disease and a new classification proposal

Andrew Lyons [a,*], Jona Osher [a], Elinor Warner [a], Ravi Kumar [a], Peter A. Brennan [b]

[a] *Head and Neck Unit, Guys and St Thomas' Hospital NHS Trust*
[b] *Portsmouth Hospitals NHS Trust, United Kingdom*

Accepted 24 February 2014
Available online 13 April 2014

Abstract

Osteoradionecrosis (ORN) is potentially a debilitating and serious consequence of radiotherapy to the head and neck. Although it is often defined as an area of exposed bone that does not heal, it can also exist without breaching the mucosa or the skin. Currently, 3 classifications of ORN are in use, but they depend on the use of hyperbaric oxygen or are too complicated to be used as a simple aide-mémoire, and include features that do not necessarily influence its clinical management. We propose a new classification to cover these shortcomings and to take into account the increasingly widespread use of antifibrotic medical treatment. We classified a series of 85 patients with varying severities of ORN into 4 groups. An analysis of the outcomes of the series showed that the classification staged the severity of the condition simply and that the stage was relevant to both treatment and outcome. The new classification was therefore verified by the series presented.
© 2014 The British Association of Oral and Maxillofacial Surgeons. Published by Elsevier Ltd. All rights reserved.

Keywords: Osteoradionecrosis; Classification; Mandible; Maxilla; Head and neck cancer; Radiotherapy

Introduction

Previous classifications

Osteoradionecrosis (ORN) is a condition that afflicts between 2% and 22% of patients who have radiotherapy to the head and neck.[1] It is often defined as an area of exposed bone that persists for 3 months or longer when all other diagnoses have been excluded.[1–3] However, this is not correct, as ORN can be shown radiographically without any breach of the oral mucosa or cervicofacial skin, by virtue of its characteristic appearance (Fig. 1). This variant was included in a classification by Støre and Boysen.[1] The severity of the condition and its effect on the patient vary from cases that are entirely asymptomatic to those that cause severe pain, disfigurement, and functional impairment of the jaws, and which seriously impair a patient's quality of life.

As the effects of the condition vary so widely, several classifications have been developed over the past 30 years to aid its management. The 3 currently in widespread use are based on the pathophysiology of the condition. In 1983 Marx[4] described ORN as emanating from a triad of hypoxia, hypocellularity, and hypovascularity. As a logical solution to this aetiology he developed specific treatments that involved the use of hyperbaric oxygen (HBO), which could be used as the sole treatment or as an adjunct depending on the presenting features of the condition or the patient's response to it. He then developed and published a classification essentially based on the patient's response to HBO.[5] Although he based

* Corresponding author at: Head and Neck Unit, Guys and St Thomas' Hospital NHS Trust, Great Maze Pond, London SE1 9RT, United Kingdom. Tel.: +044 207 1884344; fax: +044 207 18821281.
E-mail address: andrew.lyons@gstt.nhs.uk (A. Lyons).

http://dx.doi.org/10.1016/j.bjoms.2014.02.017
0266-4356/© 2014 The British Association of Oral and Maxillofacial Surgeons. Published by Elsevier Ltd. All rights reserved.

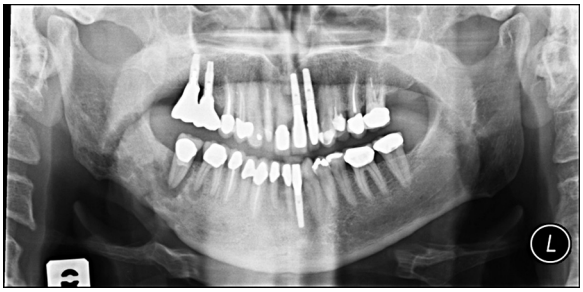

Fig. 1. Extensive osteoradionecrosis of the right angle and body of the mandible without bony exposure.

the guidelines for management on the response to HBO rather than on the clinical signs and symptoms, clinicians must have found it useful, as it is still used fairly widely 3 decades later. Epstein et al. published a classification in 1987[3] that is also widely used. It includes 3 categories: healed, chronic but non-progressive, and active progressive.

Both classifications undoubtedly have merits but both involve the use of HBO, which as a single treatment has been proved to be ineffective.[6] Although a recent Cochrane Review[7] concluded that HBO might be marginally helpful as an adjunctive treatment, the results of studies into its efficacy have been variable.[7] As a consequence many clinicians do not use it, and it renders the Marx classification invalid. Although Epstein et al. mention the use of HBO it is by no means fundamental, and as their classification relies largely on whether the condition is progressive or stable, it still has some merit. However, even this has its faults, as the management of ORN is largely based on actual signs and symptoms and whether it is progressing or not; if it has resolved it can be argued that it has no place in a classification. The 3 main categories are subdivided into 3 further categories based on the presence of pathological fracture, which although important, does not necessarily alter the management, and unfortunately turns an easily remembered 3-stage classification into a 6-stage one that is more complex and less memorable.

In a third, more recent classification, Notani et al.[8] graded ORN according to its anatomical extent, which has important implications for management as shown by the series of patients who were treated to formulate it. However, it does not mention symptoms, which are crucial in the management of the condition.

Since Marx described the pathophysiology of ORN, no other explanations were offered until Delanian et al., published the fibroatrophic theory in 1993.[9] They described 3 distinct phases. The first is a pre-fibrotic phase in which changes in endothelial cells predominate with an acute inflammatory response. The second is a constitutive, organised phase in which abnormal fibroblastic activity predominates, and the extracellular matrix becomes disorganised. Finally, in the late fibroatrophic phase, attempted tissue remodelling forms fragile healed tissues, which have a serious inherent risk of late reactivated inflammation in the event of local injury, and in bone may result in necrosis. The fibroatrophic theory supposes that the changes in bone that cause this process are very similar to those that occur when physical injuries affect other tissues in the body such as the lungs and liver.[10]

Apart from undermining the treatment of ORN by HBO and by inference the classifications by Marx and Epstein et al., this aetiology will also be useful in developing new treatments. Pentoxifylline is a vasodilator that has antifibrotic effects. Several publications describe its success alone or in combination with vitamin E as an antioxidant to treat fibrosis after radiotherapy and after chemical damage to a number of organs, although the precise mode of action in ameliorating radiation fibrosis is unclear.[11,12] A prospective randomised trial has also confirmed the benefit of pentoxifylline in cirrhosis of the liver.[13]

Pentoxifylline and vitamin E have been used to great effect in treating small areas of ORN with visual and symptomatic resolution of the condition.[14–17] Larger areas might be stabilised but they will not resolve with this treatment.[16] However, ORN requires treatment only if there is pain, impaired function, or active infection. In the absence of HBO, the only other option for treatment is operation, which is potentially problematic. Debridement of inflamed and fragile fibroatrophic bone, coupled with the inability of irradiated soft tissues to cover exposed bone adequately, may worsen the condition and convert relatively stable ORN into a progressive type. If it is accepted that HBO has at best a marginal role, when other measures have failed, probably the best option for treatment of symptomatic ORN that is larger than 2.5 cm but not extensive (including that covered by mucosa), is limited surgical treatment to cover the bone with new tissue from outside the radiation field, as described by Harris.[2] When it is extensive and symptomatic, free tissue transfer may be the optimum but not necessarily the best option.[18]

With the increasing use of pentoxifylline but not HBO, and in the absence of a classification that includes the extent of ORN and its symptoms, we have developed a new classification and have used it in a series of patients with the condition (Table 1).

Method

After reviewing the outcomes of 85 patients (Table 2) who had been treated for ORN including 33 who underwent free tissue transfer, we developed a new classification to aid in the management of the condition (Table 1). The characteristics and original disease were not included, as they do not contribute to the proposed classification, which is based on the extent of the condition and its management.

Results

All our patients could be classified using this system (Tables 1 and 2). They were all prescribed pentoxifylline

Table 1
Classification of osteoradionecrosis.

Stage	Description
1	<2.5 cm length of bone affected (damaged or exposed); asymptomatic Medical treatment only
2	>2.5 cm length of bone; asymptomatic, including pathological fracture or involvement of inferior dental nerve, or both Medical treatment only unless there is dental sepsis or obviously loose, necrotic bone
3	>2.5 cm length of bone; symptomatic, but with no other features despite medical treatment Consider debridement of loose or necrotic bone, and local pedicled flap
4	2.5 cm length of bone; pathological fracture, involvement of inferior dental nerve, or orocutaneous fistula, or a combination Reconstruction with free flap if patient's overall condition allows

400 mg twice a day and vitamin E 100 units once a day for between one and 24 months. At some point they also had a course of antibiotics. Treatment was curative in all patients who had less than 2.5 cm of exposed bone (stage 1). In more advanced cases treatment was used to stabilise the condition or control the symptoms. Four patients in group one ($n = 28$) were prescribed clodronate for up to 3 months. Five patients had partially sequestered bone removed (1 in stage 2, and 4 in stage 3); 2 of the patients in stage 3 also had the bone curetted with a hand instrument. Coverage was with a nasolabial flap.

Although the disease resolved in 2 of the 12 patients with stage 3 ORN who were on pentoxifylline and vitamin E alone, 7 of them progressed to stage 4 over a period of 2–9 months.

The largest group were those with stage 4 disease ($n = 38$) as the unit is a tertiary referral centre for ORN. Of these, 33 patients had free vascular transfer and the disease resolved after varying times and further treatments; one patient had a pectoralis major myocutaneous flap. Although symptomatic, 2 patients refused treatment, and one died before it began. Only one patient in stage 4 underwent resection with no additional hard or soft tissue reconstruction. The ramus and condyle were affected (Fig. 2). Follow-up in this group ranged from 3 months to 5 years. Although there was no recurrence in the surgically treated areas, 4 patients developed ORN in new sites.

Table 2
Patients grouped according to described classification.

Stage	No. of patients	Resolved	Improved	Stable	Progressed
1	28	17	5	6	0
2	7	2	1	2	2
3	12	2[a]	1	2	7
4	38	35[b]	–	2	1

[a] With local flap.
[b] 33 had free flap, 1 pectoralis major, 1 excision and primary closure.

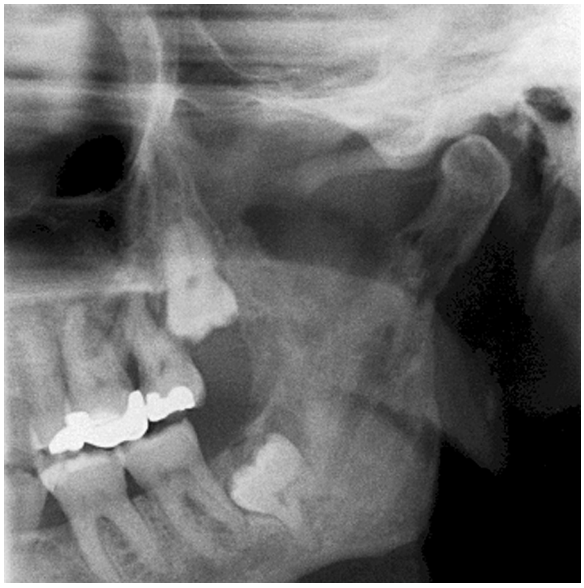

Fig. 2. Extensive osteoradionecrosis of the left condyle and ramus with extensive soft tissue coverage, which permitted excision of the ramus, condyle, and coronoid process without the necessity for tissue transfer.

Discussion

Outcomes in Table 2 show that ORN was stable in patients with early stage disease and it did not progress to higher stages during follow-up periods of at least 3 months. We cannot state categorically that early stage disease will not progress during a patient's lifetime, but the proportion would be very small. The same is not true of stage 3 disease, which in a few patients progressed to stage 4. Most of those with stage 4 disease required and consented to serious operations with reconstruction.

We do not know whether the medication stopped the condition progressing in the earlier stages. ORN may heal, regress, and stabilise spontaneously, and it is remarkable how few patients in other series have required reconstructive surgery for disease that has progressed. In the series reported by Epstein et al.[3] 57% of cases that resolved on conservative treatment were stable (15% complete resolution and 42% stable). Other authors report similar figures although in some cases conservative treatment involved sequestrectomy and other minor operations. However, in this series 23% developed pathological fractures during the study period and 19% of cases were progressive. Only 2 of our 36 patients in stage 1 or 2 progressed to higher stages.

If our new classification is applied to the series reported by Delanian et al.,[15] ORN reduced or completely resolved in all 54 patients with grade 1 or 2 disease who were prescribed pentoxifylline and vitamin E. A small series reported by McLeod et al.[16] found that only one of 12 patients progressed to a higher Epstein grade. Other reports of the successful use of pentoxifylline and vitamin E for small areas of ORN are now quite numerous.[14–17] Obviously, a prospective randomised controlled trial is required to prove the efficacy of this

regimen, but currently, even with the lower levels of evidence it is becoming compelling. If low stage ORN by our classification can be stabilised at worst, and at best cured, this further validates the usefulness of the classification. Extensive and symptomatic disease may progress rapidly but this is rarely seen in small areas of exposed bone.

Only 2 patients in our series were successfully treated with limited debridement and pedicled flaps. However, as this treatment was shown to be highly efficacious in a series of 10 patients[1], the stage 3 group does seem to have validity. In our series 33 patients who were classified as having stage 4 disease went on to have free tissue transfer, and provided their general medical condition permits this (American Society of Anesthesiologists (ASA) I or II), it is the recommended treatment. In patients with serious coexisting conditions, soft tissue reconstruction with a pedicled flap such as a pectoralis major flap is an option. Excision of dead bone with primary closure may be an option in lateral defects that are not too extensive, but they should still be classified as stage 4. However, as soft tissue closure may subsequently fail, this technique should be employed only in selected cases.

In conclusion, although ORN is a heterogeneous condition, our simple 4-stage classification seems to be validated by the cases presented in this series and by the treatment reported by other authors. While it cannot be used in every case, in most we consider it to be a helpful aid to management and the collection of data.

Conflict of interest

None.

References

1. Støre G, Boysen M. Mandibular osteoradionecrosis: clinical behaviour and diagnostic aspects. *Clin Otolaryngol Allied Sci* 2000;**25**:378–84.
2. Harris M. The conservative management of osteoradionecrosis of the mandible with ultrasound therapy. *Br J Oral Maxillofac Surg* 1992;**30**:313–8.
3. Epstein JB, Wong FL, Stevenson-Moore P. Osteoradionecrosis: clinical experience and a proposal for classification. *J Oral Maxillofac Surg* 1987;**45**:104–10.
4. Marx RE. Osteoradionecrosis: a new concept of its pathophysiology. *J Oral Maxillofac Surg* 1983;**41**:283–8.
5. Marx RE. A new concept in the treatment of osteoradionecrosis. *J Oral Maxillofac Surg* 1983;**41**:351–7.
6. Bessereau J, Annane D. Treatment of osteoradionecrosis of the jaw: the case against the use of hyperbaric oxygen. *J Oral Maxillofac Surg* 2010;**68**:1907–10.
7. Bennett MH, Feldmeier J, Hampson N, Smee R, Milross C. Hyperbaric oxygen therapy for late radiation tissue injury. *Cochrane Database Syst Rev* 2012;**5**:CD005005.
8. Notani K, Yamazaki Y, Kitada H, et al. Management of mandibular osteoradionecrosis corresponding to the severity of osteoradionecrosis and the method of radiotherapy. *Head Neck* 2003;**25**:181–6.
9. Delanian S, Martin M, Housset M. Iatrogenic fibrosis in cancerology (1): descriptive and physiopathological aspects. *Bull Cancer* 1993;**80**:192–201 [in French].
10. Delanian S, Lefaix JL. The radiation-induced fibroatrophic process: therapeutic perspective via the antioxidant pathway. *Radiother Oncol* 2004;**73**:119–31.
11. Akriviadis E, Botla R, Briggs W, Han S, Reynolds T, Shakil O. Pentoxifylline improves short-term survival in severe acute alcoholic hepatitis: a double-blind, placebo-controlled trial. *Gastroenterology* 2000;**119**:1637–48.
12. Chiao TB, Lee AJ. Role of pentoxifylline and vitamin E in attenuation of radiation-induced fibrosis. *Ann Pharmacother* 2005;**39**:516–22.
13. Sidhu SS, Goyal O, Singla M, Bhatia KL, Chhina RS, Sood A. Pentoxifylline in severe alcoholic hepatitis: a prospective, randomised trial. *J Assoc Phys India* 2012;**60**:20–2.
14. Delanian S, Depondt J, Lefaix JL. Major healing of refractory mandible osteoradionecrosis after treatment combining pentoxifylline and tocopherol: a phase II trial. *Head Neck* 2005;**27**:114–23.
15. Delanian S, Chatel C, Porcher R, Depondt J, Lefaix JL. Complete restoration of refractory mandibular osteoradionecrosis by prolonged treatment with a pentoxifylline-tocopherol-clodronate combination (PENTOCLO): a phase II trial. *Int J Radiat Oncol Biol Phys* 2011;**80**:832–9.
16. McLeod NM, Pratt CA, Mellor TK, Brennan PA. Pentoxifylline and tocopherol in the management of patients with osteoradionecrosis, the Portsmouth experience. *Br J Oral Maxillofac Surg* 2012;**50**:41–4.
17. Kahenasa N, Sung EC, Nabili V, Kelly J, Garrett N, Nishimura I. Resolution of pain and complete healing of mandibular osteoradionecrosis using pentoxifylline and tocopherol: a case report. *Oral Surg Oral Med Oral Pathol Oral Radiol* 2012;**113**:e18–23.
18. Jacobson AS, Buchbinder D, Hu K, Urken ML. Paradigm shifts in the management of osteoradionecrosis of the mandible. *Oral Oncol* 2010;**46**:795–801.